



Perineal hypospadias; The Bilateral Based (BILAB) Skin Flap Technique

Ahmed T. Hadidi *

Hypospadias Clinic, Department of Pediatric Surgery, Emma and Sana Offenbach Hospitals, Germany

ARTICLE INFO

Article history:

Received 20 July 2013

Received in revised form 29 September 2013

Accepted 30 September 2013

Key words:

Hypospadias

Urethra

Urologic surgical procedures

Flaps

Male

ABSTRACT

Purpose: The purpose of this study was to present the "bilateral based skin flap (BILAB) technique" for patients with perineal hypospadias associated with severe deep chordee and report the follow up.

Operative Principle: The short urethral plate is incised, the hypoplastic corpus spongiosum excised, the glans split in the midline, and a healthy urethral plate is reconstructed from the lateral penile skin and foreskin to the tip of the glans.

Patients and Methods: Between January 2005 and December 2011, the BILAB technique was performed in 68 patients with perineal hypospadias associated with severe chordee as a one or two stage repair. The records of 63 patients who maintained regular follow up were reviewed. The new urethra was reconstructed from the new urethral plate during the same setting in 26 patients. The remaining 37 patients had the urethroplasty performed 3–6 months later as a two stage repair. Patient age ranged from 8 months and 2 years (mean 10 months). Follow-up period ranged from 18 months to 8 years (mean 43 months).

Results: Satisfactory results were obtained in 54 patients (85%). Two children developed diverticula, two patients developed glans dehiscence, one child developed fistula, and one child had complete wound dehiscence, and urethroplasty was successfully reconstructed 6 months later. Three patients developed scar contraction 6–12 months after surgery. This was corrected by excision of the scarred intermediate layer.

Conclusions: The BILAB technique is a reliable technique for patients with perineal hypospadias. It produces slit like meatus at the tip of the glans. The surgeon may decide intra-operatively whether to complete the urethroplasty in one or two stages. Long term follow up until puberty is being carried out.

© 2014 Elsevier Inc. All rights reserved.

Perineal hypospadias remains a major challenge for the hypospadias surgeon. The lateral based flap [1], Koyanagi technique [2], Duckett Island flap [3] and Bracka two stage repair [4], are the current techniques used for perineal hypospadias [5].

Experience with the Bilateral based flap (BILAB) in patients with perineal hypospadias is reported. The principle is to incise the short urethral plate, excise the hypoplastic corpus spongiosum, split the glans and reconstruct a healthy urethral plate from the lateral penile skin and foreskin to the tip of the glans. This lateral skin is fixed to the tunica albuginea in the midline to provide stability and blood supply. The new urethra is reconstructed from the new urethral plate to the tip of the glans as a one or two stage procedure.

For the purpose of the study, perineal hypospadias (or Grade IV) is a severe form of hypospadias defined when the urethral opening lies proximal to the peno-scrotal junction, associated with severe deep chordee that requires division of the urethral plate (curvature is 45° or more during erection) and usually associated with bifid scrotum and occasionally with penoscrotal transposition.

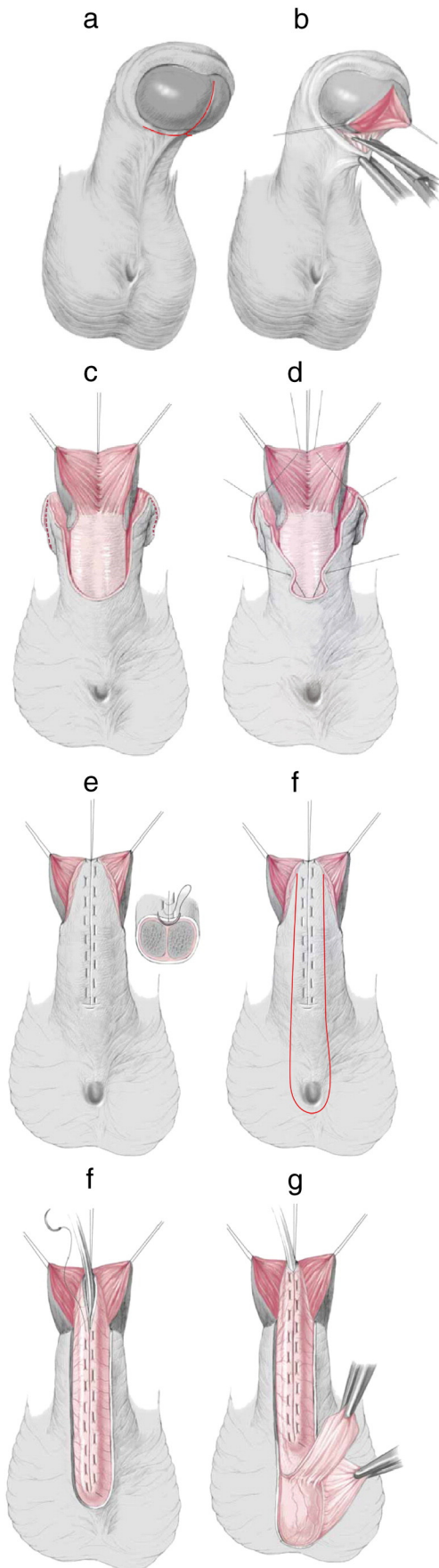
1. Patients and methods

The BILAB technique was performed in 68 patients from January 2005 to December 2011. Approval for the procedure was obtained from the hospital ethics committee. Five patients were lost for follow up and the remaining 63 patients constitute the present cohort for this report. Patient age ranged from 8 months to 2 years (mean 10 months). All the patients had perineal hypospadias with severe deep chordee. The new urethra was reconstructed during the same setting in 26 patients. The remaining 37 patients had urethroplasty performed 3–6 months later as a two stage repair. Ten patients had associated unilateral undescended testis and twelve patients had associated bilateral undescended but palpable testes. Bifid scrotum was noted in 45 of the 63 patients. Patients with bilateral undescended testes [12] underwent a standard protocol for disorders of sexual development (DSD) including chromosomal analysis, ultrasound of the abdomen, laparoscopy (3 patients), gonadal biopsy (2 patients) and cystoscopy (2 patients).

The indications to perform BILAB as a two stage procedure included; undescended testis (22 patients), narrow skin bridge and flail vascularity after excision of extensive chordee (9 patients), small glans (5 patients) and associated medical conditions that favor short anaesthesia (1 child). In those patients, orchidopexy was performed (when indicated), chordee excision and splitting the glans were

* Max-Planck Str.2, Seligenstadt, D-63500, Germany. Tel.: +49 174 205 6905; fax: +49 6182 843 0293.

E-mail address: Prof.Hadidi@hypospadizentrum.de.



performed during the first stage operation. The resultant defect on the glans and penis was covered from the lateral penile skin and foreskin and urethroplasty was performed 3–6 months later.

One child had bilateral Wilms' tumour necessitating bilateral nephrectomy. The first stage was performed while the child was on peritoneal dialysis and urethroplasty was performed 6 months later after successful living related (the mother) kidney transplantation.

A transurethral Silastic catheter was used for 7 days in all patients. An additional suprapubic catheter was kept in place for 13 days in the 26 patients who had one stage BILAB repair. Follow-up period ranged from 14 months to 8 years (mean 43 months).

1.1. Surgical Technique (Figs. 1, 2)

Under general anesthesia and caudal block, a traction suture of 4/0 Prolene is placed through the tip of the glans. A tourniquet is applied at the base of the penis and an artificial erection test is performed. Careful assessment of the penis and both testes is performed. If the child has undescended testis, little foreskin or more than 40% curvature, the urethroplasty is performed as a second stage procedure (37 patients).

1.1.1. Chordee excision (Fig. 1a)

A sub-coronal skin incision is made 3–5 mm proximal to the coronal sulcus. The incision is deepened to reach the tunica albuginea and the corpora cavernosa is freed off the short urethral plate and hypoplastic corpus spongiosum using a sharp scissor. There is usually a gritty sensation as if one is cutting through hard fibrous tissue or cartilage. Without excision of any skin, the urethral meatus usually retracts about 2 cm. As the chordee in hypospadias involves the ventral aspect of the penis only, degloving is limited to the ventral aspect of the penis. This is important to preserve the dartos fascia and blood supply to the BILAB flaps.

1.1.2. Glans split (Fig. 1b)

The glans is split in the midline from the subcoronal sulcus to the tip. The incision is deepened to allow for two large and freely mobile glanular wings and to prepare adequate space for the new urethra.

1.1.3. Incision & mobilization of the foreskin (Fig. 2c)

A transverse incision is made laterally at the muco-cutaneous junction of the foreskin on both sides. This simple step provides adequate outer foreskin to cover the glans to the tip without tension. This is different than the Koyanagi technique where the inner mucosal collar is used to form the new urethra.

1.1.4. New urethral plate (Fig. 1d, Fig. 1e)

The penile skin and foreskin are mobilized from both sides, preserving dartos fascia and sutured together in the midline with tunica albuginea (inset). Thus a healthy new type of "urethral plate" is formed that is fixed to the tunica albuginea in the midline. Additional "blanket" sutures are taken to fix the new skin to the glans and penis as required. If the surgeon decides to perform urethroplasty at a

Fig. 1. BILAB operative technique. (a) A transverse subcoronal incision is made and all the hypoplastic tissues are removed down to the tunica albuginea. (b) The glans is split in the midline like an open book to provide adequate space for the new urethra. (c) The proximal skin edge usually retracts to the proximal penis and a transverse lateral skin incision in the prepuce at the junction between the outer skin and inner mucosa in both sides. (d) Both medial edges are fixed together in the midline to the tip of the glans creating a new urethral plate that is well fixed to the tunica albuginea in the midline (inset) as well as laterally. (e) A U-shaped incision is made around a catheter size F12. (f) Urethroplasty is completed with continuous subcuticular sutures, in two layers. (g) A second protective layer is mobilised from the scrotal dartos/tunica vaginalis and the remaining penile and foreskin are tailored to cover the penis and glans (from Hadidi AT with permission).

second operation, he may stop at this stage, insert a trans-urethral catheter into the bladder and apply a dressing for 3 days.

1.1.5. Urethroplasty (Fig. 1f)

A size F12 catheter is inserted into the bladder and the adequate width of the new urethra is determined by using 2–3 stay sutures that allow covering of the catheter with skin. The flap edges are tailor cut step by step using a sharp scissor (to preserve the fascia carrying blood supply to the flap). We do not recommend cutting the whole length of the flap at once but rather cut one third, suture, and then cut another third then suture etc. The aim is to avoid having a redundant or narrow new urethra (Fig. 2f). Urethroplasty is performed using a continuous 6/0 polyglactin mattress suture on a cutting needle. (Fig. 2g). A small V is excised from the apex of the BILAB flap (inset) [6]. If there is redundant dartos tissue available, a second layer of continuous 7/0 polyglactin is sewn over the urethroplasty for support.

1.1.6. Protective intermediate layer (Fig. 1g)

A protective intermediate layer from the scrotal dartos/tunica vaginalis is routinely used to cover the urethroplasty (Fig. 2i). If there is adequate penile dartos fascia, another layer is created between the neo-urethra and the scrotal layer (Fig. 2h).

1.1.7. Meatoplasty and Glanuloplasty

The two edges of the final meatus are sutured together in the center of the V creating a slit like meatus using a single stitch of 7/0 polyglactin. No other sutures are required for the meatus. The glanular wings are approximated using interrupted 7/0 polyglactin transverse mattress sutures. The remaining wound is closed using a continuous 7/0 polyglactin mattress stitch.

The remaining skin of the penis and foreskin was fashioned to provide ventral skin coverage of the penis. This is not always easy depending on the width of the flap used in the urethroplasty and the available penile skin. One patient had severe chordee and hypoplasia and the foreskin was brought down to cover the ventral penile surface through a button hole in the prepuce.

1.1.8. Urine drainage

A transurethral Silastic catheter is retained for 7 days. If the BILAB technique is performed as a one stage procedure, an additional suprapubic catheter is inserted into the bladder for 13 days. The aim is to allow adequate time for the edema to subside before allowing urine to pass through the new urethra.

1.1.9. Dressing

All patients had a standard dressing in the form of gentamicin local ointment, gauze and adhesive tape that compresses the penis, gauze and catheter against the lower abdominal wall and allows free mobility of the patient [7]. The dressing is removed at the time of removal of the transurethral catheter and the penis is left exposed. If the dressing became wet with urine or blood, the dressing was changed using a similar standard dressing. Broad spectrum antibiotics (second generation cephalosporin) were administered for one week. Paracetamol and ibuprofen suppositories and syrup were routinely used for pain relief as required.

The standard follow up protocol in the hypospadias centre includes examination after 3 months, 12 months and every 2–3 years till the age of 15 years. Patients living long distances from the center and who failed to attend for follow up were contacted by

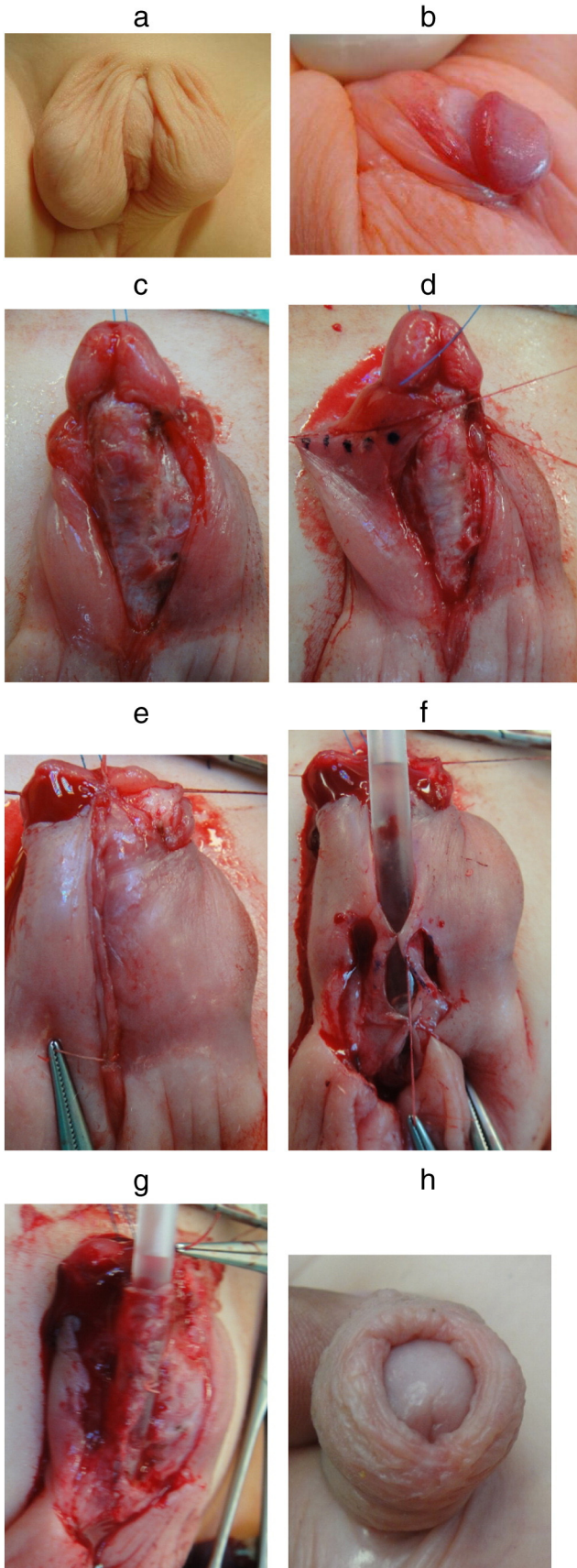


Fig. 2. The one stage BILAB. (a, b) Pre-operative photos. (c) After incision of the short urethral plate and complete excision of the hypoplastic corpus spongiosum. (d) The dotted line shows the origin of the flap that will form the right half of the new urethral plate. (e) After reconstruction of the new urethral plate. (f) The tailor step approach to ensure having the exact diameter of the new urethra. (g) After urethroplasty. (h) Appearance one year after surgery.

e-mail and phone using a structured questionnaire [8]. Follow up period ranged from 14 months to 8 years (mean 43 months). Five patients were lost to follow up.

The results were assessed by an independent outpatient nurse who assessed the functional results as well as the site, shape of the meatus and the degree of residual curvature if present. Results were considered satisfactory when the boy achieves an apical slit-like meatus at the tip of the glans penis, single forward stream, unimpeded voiding, good cosmesis and no need for secondary surgery for the urethra. Uroflowmetry was performed in toilet trained children (9 patients). Peak flow within 2 standard deviations was considered normal [9].

1.1.10. Results & complications (Figs. 2, 3)

Sixty three patients maintained regular follow up, the remaining being from long distances and have not responded to communications which are poor in some areas. Follow up period ranged from 18 months to 8 years (mean 43 months). Satisfactory results were achieved in 54 patients (85%). Two children developed diverticula, two patients developed glans dehiscence, one child developed a fistula and one child had complete wound dehiscence (urethroplasty was successfully reconstructed, 6 months later). Three patients developed scar contraction 6–12 months after surgery. This was corrected by excision of scarred intermediate layer.

The fistula was closed after 6 months. A second intermediate layer was always used to protect the fistula closure. The two children with dehisced glans had meato-glanuloplasty performed successfully 6 months after the first operation.

Uroflowmetry was performed in 9 toilet trained children and the peak flow was within 2 standard deviations in 7 patients and flat in 2 patients. Those two patients are clinically free of symptoms and ultrasound of the urinary bladder did not show thickened bladder wall suggestive of distal obstruction.

2. Discussion

In the literature several publications [10–12] use the term “severe hypospadias” to describe patients with very proximal hypospadias

associated with severe deep chordee. The problem with this term is that it is unclear [10] and what is considered “severe” for one surgeon may not be that “severe” for another. Therefore, the author prefers to use the term perineal (or Grade IV hypospadias [5]) with well defined location of the meatus proximal to penoscrotal junction and the term severe, deep chordee is clearly defined as one that necessitates division of the urethral plate to correct the penile curvature.

Surgical correction of perineal hypospadias is the most difficult and technically demanding procedure in hypospadias surgery and remains a major challenge even for the most experienced surgeon. Current techniques could be classified into one or two stage repair. The two stage repairs entails the use of either flaps or grafts (skin or buccal mucosa) to cover the ventral surface of the penis after division of the urethral plate and excision of the hypoplastic ventral structures and urethroplasty is performed as a second stage. One stage repairs include the Preputial Island Tube (Duckett) PIT urethroplasty [13], the lateral based flap (LAB) [1] technique, the Koyanagi repair [2] and its modifications [14,15].

There have been major shifts in the trends for management of perineal hypospadias during the past few decades. In the 1960s and 1970s, the 2-stage repair was the standard. In the 1980s 1-stage repair became popular due to the increased use of preputial flaps. In the 1990s there has been shift from preputial island tube urethroplasty [3] to preputial island onlay flaps [6] when the urethral plate could be spared because it is associated with relatively fewer complications. However, that meant extensive use of dorsal plication and inadequate excision of the ventral hypoplastic tissues and unnecessary shortening of the penis. In 1995 Bracka presented a personal series of 600 cases and advocated a two-stage repair using full-thickness skin grafts [4].

The pendulum has swung back due to unsatisfactory results with dorsal plication and extensive mobilization under the urethral plate. Several reports in 2000s strongly recommended two stage repair for severe and perineal hypospadias [16–18]. Catti et al. [19] reported that division and proximal mobilization of the plate allowed them to achieve complete penile straightening in 51 of 57 cases (89%). Braga et al. [20] reported that none of their patients undergoing simultaneous dorsal plication and urethral plate transection had curvature recurrence, compared to 19 of 52 (37%) undergoing dorsal plication

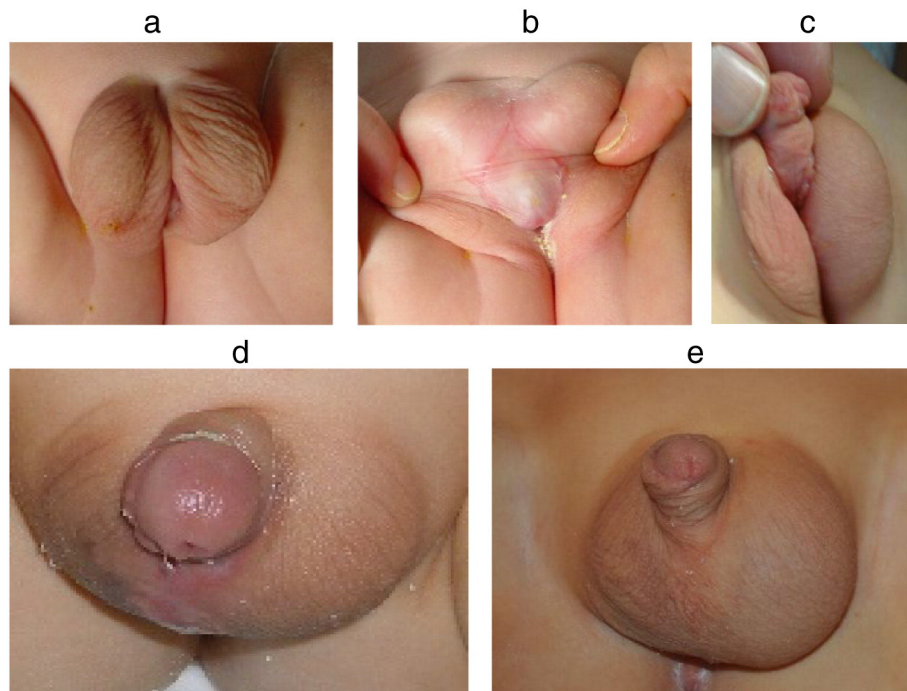


Fig. 3. The two stage BILAB flap technique. (a, b) Pre-operative photos. (c) After healing of the first stage. (d) One month after the second stage. (e) One year after the second stage.

alone ($p = 0.002$). In the present study division and extensive excision of the hypoplastic corpus spongiosum allowed complete penile straightening in 60 of the 63 patients (95%). The remaining 3 patients had curvature of 10° and this was considered acceptable and no dorsal plication was performed in any of the patients in the study.

There are advantages and disadvantages of one-stage repair for perineal hypospadias. Jyanathi [15] suggested that one-stage repair has the advantage of saving the child a second operation and also performing urethroplasty in a virgin field without the risk of having scars. In the author's experience, scarring was never a problem if the urethroplasty was performed as a 2 stage-repair.

How wide should we reconstruct the new urethra? The distal new urethra should be as wide as the original urethra, otherwise the new urethra will be narrower than the proximal one with increased incidence of fistula and stricture formation. The author uses a size F12 catheter as a routine as long as the proximal urethra accommodates it. In patients with small glans, splitting the glans helps to make space for an F12 catheter. Nevertheless, glans dehiscence did occur in 2 patients with small glans in the present study.

Surgical correction of perineal hypospadias requires meticulous and extensive chordee dissection and excision of the ventral hypoplastic structures in addition to division of the urethral plate. This results in significant post-operative edema and requires urinary diversion for 14 days if the urethroplasty is performed as a one stage repair. The author uses a supra-pubic catheter routinely if the urethroplasty is performed in one stage to avoid mucosal irritation that impairs healing when a catheter is left within the urethra for more than 7 days. If urethroplasty is performed as a second stage, there is no need to use a supra-pubic catheter.

Hadidi reported his experience with the Lateral based flap (LAB) for proximal hypospadias and deep chordee with satisfactory results in 91% of the patients [1]. When applying the LAB flap technique in perineal hypospadias, it was found that the very proximal position of the meatus and the severity of chordee to be corrected resulted in rotation of the penis, difficulty in mobilizing the remaining skin to cover the penis and the new urethra and severe post-operative edema.

The BILAB flap is a natural forward development of the original (LAB) flap technique by applying the Koyanagi [2] principle and using the lateral penile skin from both sides. It differs from the original Koyanagi in the following points:

- 1) the outer preputial foreskin is used and not the inner mucosa. This may reduce the possibility of diverticula as the outer skin is less likely to balloon and cause a diverticulum.
- 2) The 2 lateral flaps are sutured together with tunica albuginea in the midline. This allows for fixation of the flaps and underlying fascia to the midline and creation of a new urethral plate. It also reduces manipulation of the dartos fascia carrying blood supply to the flaps.
- 3) The glans is incised deeply in the midline and the two lateral flaps are fixed to the tip of the glans before tubularisation. This allows having a slit like meatus at the tip of the glans.
- 4) The technique is easily reproducible and the width of the new urethra can be accurately controlled around a catheter F12 for reconstruction of a new healthy urethral plate.
- 5) Depending on the amount of foreskin available, there was a chance to fulfill the wish of the parents and do foreskin reconstruction in 24 of the 63 patients included in the study.
- 6) The BILAB is flexible and can be used as a one or two-stage procedure.

The BILAB has the advantage over the classic LAB flap in that it is more symmetrical, reduces the chances of rotation and allows for equal skin flaps from both sides to cover the penis in a more natural manner. In addition, it provides flexibility to the surgeon as it can be done as a two stage repair.

The use of scrotal dartos/tunica vaginalis as a protective intermediate layer has dramatically reduced the incidence of fistula (one fistula in 63 patients). Fistula used to be the commonest complication following hypospadias repair [21]. With the routine use of protective intermediate layer and the scrotal dartos fascia/tunica vaginalis as a protective intermediate layer, the incidence of fistula has declined dramatically. However, the scrotal dartos/tunica vaginalis has the disadvantage that it occasionally contracts during healing which may require excision later as was the case with 3 patients included in the study.

It was interesting that the two children, who developed diverticula 3–6 months after urethroplasty, were among the 26 patients who had urethroplasty performed as a one stage repair. There are probably two predisposing factors: the lack of rigid supportive tissue and relative distal narrowing.

Uroflowmetry was carried out in 9 toilet trained children following BILAB repair. Two children had a flat curve although they did not have any clinical symptoms of obstructive voiding and ultrasound on the bladder did not show increased bladder wall thickness. The significance of uroflow following hypospadias repair remains uncertain [10].

The use of antibiotics in hypospadias surgery is a controversial issue with different surgeons espousing different protocols [22]. Acknowledging the fact that hypospadias surgery is performed in a potentially infected area near the anus and infection could have a very serious consequence on the patient, the author uses antibiotics routinely after hypospadias surgery as long as the patient has a catheter (foreign body) in place.

The BILAB flap offers the surgeon the flexibility during the operation to decide whether to proceed and perform urethroplasty during the first operation or to defer it to a second operation 3–6 months later. The following factors influence decision making:

- 1) Associated undescended testis: It is better to perform orchidopexy, chordectomy and glans split as the first stage and perform urethroplasty as a second stage.
- 2) The severity of chordee: If the surgeon realizes that the bridge of fascia and tissues bringing blood supply to the skin flap is narrow and compromised, it is wise to postpone urethroplasty to a second stage 3 months later.
- 3) Flat small glans: This is a relative indication to plan to split the glans in the first stage, line it with skin and postpone urethroplasty 3 months later.
- 4) Associated medical conditions: where it is preferable to avoid long anaesthesia.

The BILAB flap technique was associated with low morbidity and low complication in the short term follow up (mean 43 months). Long term follow up is being carried out to assess the functional and cosmetic outcome after puberty.

References

- [1] Hadidi AT. Lateral based flap: a single stage urethral reconstruction for proximal hypospadias. *J Pediatr Surg* 2009;44:797–801.
- [2] Koyanagi T, Matsuno T, Nonomura K, et al. Complete repair of severe penoscrotal hypospadias in 1 stage: experience with urethral mobilization, wing-flap-flipping urethroplasty and 'glanulomeatoplasty'. *J Urol* 1983;130:1150–4.
- [3] Duckett JW, Baskin LS. Hypospadias. In: Gillenwater JY, Grayback JT, Howards SS, Duckett JW, editors. *Adult and pediatric urology*. 3rd ed. St. Louis: Mosby-Year Book; 1996. p. 2549–89.
- [4] Bracka A. Hypospadias repair: the two-stage alternative. *Br J Urol* 1995;76(Suppl. 3): 31–41.
- [5] Hadidi A. Proximal hypospadias with small flat glans: The lateral based only (LABO) flap technique. *J Pediatr Surg* 2012;47:2151–7.
- [6] Elder JS, Duckett JW, Snyder HM. Onlay island flap in the repair of mid and distal penile hypospadias without chordee. *J Urol* 1987;138:376–9.
- [7] Hadidi AT. Double Y glanuloplasty for glanular hypospadias. *J Pediatr Surg* 2010;45:655–60.
- [8] Hadidi AT. The Slit-Like adjusted Mathieu (SLAM) technique for distal hypospadias. *J Pediatr Surg* 2012;47:797–801.

- [9] Weber DM, Schönbucher VB, Landolt MA, et al. The Pediatric Perception Score: an instrument for patient self assessment and surgeon evaluation after hypospadias repair. *J Urol* 2008;180:1080–8.
- [10] Castagnetti M, El-Ghoneimi A. Surgical management of primary severe hypospadias in children: systematic 20-year review. *J Urol* 2010;184:1469–75.
- [11] de Mattos e Silva E, Gorduzi DB, Catti M, et al. Outcome of severe hypospadias repair using three different techniques. *J Pediatr Urol* 2009;5:205–11.
- [12] Castagnetti M, Zhapa E, Rigamonti W. Primary severe hypospadias: comparison of reoperation rates and parental perception of urinary symptoms and cosmetic outcomes among 4 repairs. *J Urol* 2013;189:1508–13.
- [13] Patel RP, Shukla AR, Snyder III HM. The island tube and island onlay hypospadias repairs offer excellent long-term outcomes: a 14-year followup. *J Urol* 2004;172:1717–9.
- [14] Hayashi Y, Kojima Y, Mizuno K, et al. The modified Koyanagi repair for severe proximal hypospadias. *BJU Int* 2001;87:235–8.
- [15] Jayanthi VR. The modified Koyanagi hypospadias repair for the one stage repair of proximal hypospadias. *Indian J Urol* 2008;24:206–9.
- [16] Gershbaum MD, Stock JA, Hanna MK. A case for 2-stage repair of perineoscrotal hypospadias with severe chordee. *J Urol* 2002;168:1727–9.
- [17] Lam PN, Greenfield SP, Williot P. 2-Stage repair in infancy for severe hypospadias with chordee: long-term results after puberty. *J Urol* 2005;174:1567–72.
- [18] Johal NS, Nitkunan T, O'Malley K, et al. The two-stage repair for severe primary hypospadias. *Eur Urol* 2006;50:366–71.
- [19] Catti M, Lottmann H, Babloyan S, et al. Original Koyanagi urethroplasty versus modified Hayashi technique: outcome in 57 patients. *J Pediatr Urol* 2009;5:300–6.
- [20] Braga LH, Lorenzo AJ, Bägli DJ, et al. Ventral penile lengthening versus dorsal plication for severe ventral curvature in children with proximal hypospadias. *J Urol* 2008;180:1743–8 [Suppl].
- [21] Hadidi AT. Fistula repair. In: Hadidi AT, Azmy AF, editors. *Hypospadias surgery, an illustrated guide*. Berlin-Heidelberg: Springer-Verlag; 2004. p. 277–82 [Chapter 28.2].
- [22] Ben Meir D, Livne PM. Is prophylactic antibacterial treatment necessary after hypospadias repair? *J Urol* 2004;171:2621–2.